

Squamous Cell Carcinoma Arising In A Mature Cystic Teratoma, An Unusual Presentation As Pain Abdomen

JB Singh, Shazia Bashir, Kirpal Kour *, Shaveta Sharma, Athar Hafiz

Abstract

Germ cell tumors constitute approximately 20%- 30% of all ovarian tumors. Mature cystic teratomas account for 95% of germ cell tumors. Malignant transformation in a mature cystic teratoma of the ovary is a rare event, developing in 1 to 2 % of cases with squamous cell carcinoma being the most common malignant transformation (75%). We report a case of malignant transformation in mature cystic teratoma of the ovary in a 45 year old multiparous woman who had presented with pain abdomen for last two months. Pain was not relieved by symptomatic measures and therefore investigations were carried out. Radiological investigations revealed bilateral ovarian teratoma. During laprotomy a large cystic mass was seen arising from the left ovary that was adherent to the large gut. Right ovary was also found to be enlarged. Final histological diagnosis of bilateral cystic teratoma of ovaries with malignant squamous cell carcinoma arising in left ovarian teratoma was made.

Key Words

Angiosarcoma, spleen, histopathology, immunohistochemistry

Introduction

Mature cystic teratoma is the most common tumor of ovary and constitutes approximately 10 to 20% of all ovarian tumors in the women of reproductive age group. These tumors are composed of all the three germ cell layers i.e, endoderm, mesoderm and ectoderm (1). Nearly 15% of the mature cystic teratomas are bilateral (2). Malignant transformation in mature cystic teratoma is a rare event with an incidence rate of 1 to 2% (3). Malignant transformation in these tumors occurs most commonly in the form of squamous cell carcinoma (75%) followed by adenocarcinoma and melanoma (4,5). In the present report we describe a case of bilateral mature cystic teratoma of ovaries with malignant transformation to squamous cell carcinoma in left ovarian teratoma..

Case Report

A 35 year old multiparous woman presented with pain lower abdomen for two months. The pain was more severe on left side and was radiating to the lower back. Patient was having scanty irregular periods for past few months and had two previous normal vaginal deliveries and had her last delivery 10 years back. Blood pressure was 110/70. On examination, pelvic mass was felt but

there was no ascites. On vaginal examination, a large mass was felt in the left fornix. A clinical diagnosis of benign ovarian tumor was made. The laboratory findings were as follows: Hb. 9.1gm%, both MCH (24.8pg), and MCHC (29.3g/dl) were slightly below the normal range, CA 125 was 14.20U/ml (reference range: 2.0- 35), and rest of the hematological profile was within normal limits. Computerised tomography showed bilateral ovarian dermoid with left ovarian dermoid showing large thick cystic, small fatty component and an enhancing nodule. The patient was operated and total abdominal hysterectomy with bilateral salphingo oophorectomy was done. On opening the abdomen, a large cystic mass arising from left ovary was seen. The mass was in pouch of douglas, adherent to the large gut and was hemorrhagic. Right ovary was also seen to be enlarged. Post operative period was uneventful.

Pathological Findings: Macroscopic examination: Left ovary was received in multiple pieces altogether measuring 11x11x13 cms. Externally the capsule was breached. On cutting open, both solid as well as cystic areas were identified. Cut section of solid areas was grey

From the Department of Pathology, SKIMS-MCH & Obst & Gyane* LD Hospital, Srinagar (J&K)- India

Correspondence to : Dr JB Singh Assistant Prof of Pathology, Department of Pathology SKIMS-MCH Srinagar

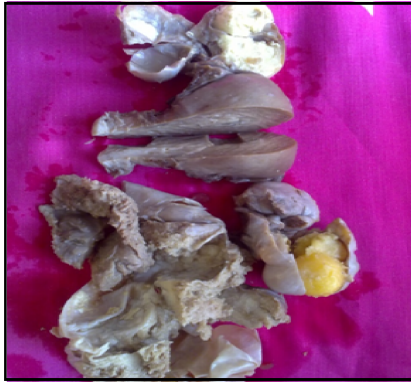

Fig.1 Ovarian Dermoid (Macroscopic Picture)

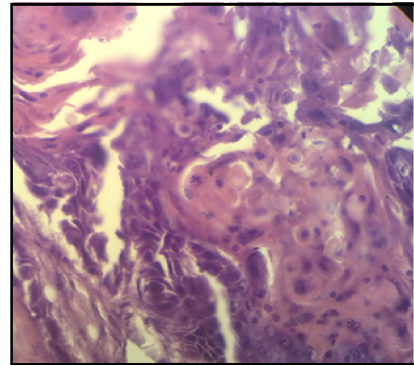


Fig 2. Photomicrograph showing Squamous cell carcinoma Ovary

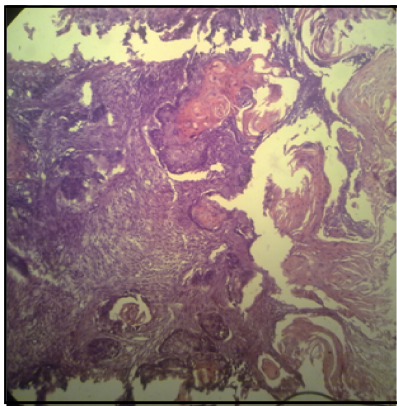


Fig.3 SCC in Ovarian Dermoid Cyst Ovary

white and firm. Cystic areas were filled with thick whitish greasy material and hair was also identified. Right ovary was also enlarged measuring 6x5x4cms. Externally the capsule was smooth and on cutting open the ovary was cystic, filled with thick whitish greasy material and hair. Uterus was grossly unremarkable. Bilateral fallopian tubes were grossly unremarkable. No lymph nodes were identified. Microscopic examination: Left ovary showed a well differentiated squamous cell carcinoma arising from mature cystic teratoma. Sections from right ovary showed mature cystic teratoma. Sections from endometrium, myometrium cervix and bilateral fallopian tubes were unremarkable. Final diagnosis of bilateral mature cystic teratoma of ovaries with malignant transformation to squamous cell carcinoma in left ovary was made.

Discussion

Squamous cell carcinoma arising from mature cystic teratoma is a rare pathologic occurrence accounting for 1 to 2% of cases and is usually not diagnosed preoperatively (6). Mature cystic teratomas are frequently bilateral but malignant change has been usually reported only on one side. In approximately 80% of cases, squamous cell carcinoma arising in a mature cystic teratoma develops

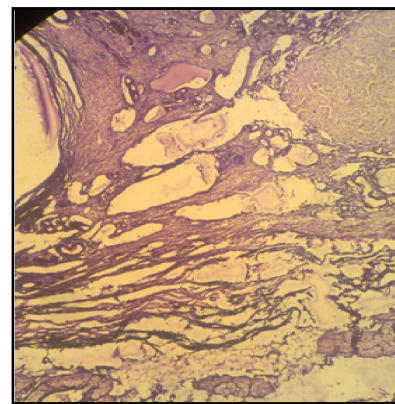


Fig. 4 Dermoid Cyst Ovary

from epidermal elements (7). Squamous cell carcinoma can also be metastatic from any other site especially the cervix (8). In our case the squamous cell carcinoma was arising from the epidermal lining of the cyst wall and, no metastatic source was found. Malignant change in the form of squamous cell carcinoma in a mature cystic teratoma occurs in women over the age of 40 years. With increase in age, the frequency of malignant change increases, rising to 19% in women after menopause (9). However reported cases of this malignant change have also been reported on young patients around 30 years of age (10). In our case, age of the patient was 35 years which was younger than the average age for the occurrence of the malignant change.

Most of the patients present with abdominal pain followed by a mass. Some of the patients may be asymptomatic or may have symptoms of abdominal distention. Some of the patients may present with the symptoms occurring due to the invasion of the nearby organs such as gastrointestinal symptoms (diarrhea, constipation, rectal bleeding) or urinary frequency (11). In our case the patient presented with pain lower abdomen that was radiating to back. The pain was more severe on

left side. She was also having scanty and irregular periods for past few months. On gross examination, the growth may be identified as cauliflower exophytic, infiltrative grey white plaques or thickening of cyst wall with necrosis and hemorrhage. In our case the large cystic mass was received in multiple pieces altogether measuring 11x11x13cms. Inner surface of the cyst was showing grey white papillary excrescences. Kikkawa *et al.* reported that a total diameter larger than 9.9cms was 86% sensitive for malignancy in their series (12).

Histologically, squamous cell carcinoma arising in mature cystic teratoma can be seen as nests of squamous cells infiltrating the stroma or malignant squamous cells lining the cyst wall. Other microscopic patterns include papillary, verruciform, insular as well as spindle cell pattern. In high grade tumors squamous differentiation may not be apparent (13). In our case tumor was graded as a well differentiated squamous cell carcinoma with the malignant squamous cells infiltrating the stroma in sheets with abundant keratin pearl formation.

It is very difficult to make a preoperative diagnosis of malignant transformation in a mature cystic teratoma clinically, because this tumor cannot be readily differentiated from an uncomplicated mature cystic teratoma or other ovarian tumors (11). However preoperative risk assessment can be aided by studying the tumor imaging characteristics. Characteristic computerized tomography findings according to Lai *et al.* are adnexal mass with fat, calcification, soft tissue component and areas of invasion through the teratoma wall must raise a suspicion of associated malignancy (14). In our case the malignant nature of the tumor could not be made preoperatively and the radiological impression of bilateral ovarian dermoids was made with left ovarian dermoid showing thick cystic, small fatty component and an enhancing nodule.

CA125 can be of help in differentiating cases of squamous cell carcinoma from other types of ovarian malignancies. It is usually normal or moderately elevated in squamous cell carcinoma but very high levels are seen in other aggressive ovarian malignancies (15). CA125 in our case was within normal range (14.20U/ml).

In several previous studies the prognosis of this tumor is often reported to be very poor. Tumor stage is regarded as one of the most important prognostic indicator. Several other factors that have been linked to unfavourable prognosis are tumor grade, cyst wall invasion, tumor dissemination, rupture, adhesion, ascitis, growth pattern, and vascular invasion (16,17).

References

1. Kurman R J. Blaustein's Pathology of the Female Genital Tract. 5th ed. New York: Springer Verlag; 2002.pp.234
2. Pfeifer SM, Gosman GG. Evaluation of adnexal masses in adolescents. *Pediatr Clin North Am* 1999;46:573- 592.
3. Young RH, Clement PB, Scully RE. Sex Cord - Stromal, Steroid Cell, & Germ Cell Tumors of the Ovary. Chapter 55. In Sternberg's Diagnostic Surgical Pathology.- 4th edition, 1921, Vol 3.pp. 2579-15.
4. Nogales F, Talerma A, Kubik-Huch RA, Tavassoli FA, Shisheboran DM. Germ Cell Tumors In World Health Organisation Classification of tumors, Pathology & Genetics of Tumors of the Breast & Female Genital Organs. Edited by Fattaneh A. Tavassoli, Peter Devilee 2003.pp. 163-175.
5. Rosai J. Female Reproductive System, Chapter 19. In: Rosai J, editor. Ackerman's Surgical Pathology. 9th ed., Vol 2 St Louis: Mosby; 2004.pp. 1649 - 1736.
6. Stamp GWH, McConnell EM. Malignancy arising in ovarian cystic teratomas- A report of 24 cases. *Br J Obstet Gynaecol* 1983; 90: 671- 675.
7. Peterson WF. Malignant degeneration of Benign Cystic Teratoma of the Ovary: A collective review of the literature. *Obstet Gynecol Surv* 1957; 12:793-830.
8. Shingleton HM, Middleton FF, Gore H. Squamous cell carcinoma in the ovary. *Am J Obstet Gynecol* 1974; 120: 556-60.
9. Anderson MC. Tumors of the ovary 4: germ cell tumors Chapter 20 In: Symmers St. W. C. Systemic Pathology by 38 authors, Gynaecological Pathology: 2nd edition, 2013 .pp. 367-92.
10. Kikkawa F, Ishikawa H, Tamakoshi K, *et al.* Squamous Cell Carcinoma arising from mature cystic teratoma of the ovary : A clinicopathologic analysis. *Obstet Gynaecol* 1997; 89:1017 - 1022.
11. Torbaghan SS, Aleagha ME, Sedighi S, *et al.* Squamous Cell Carcinoma arising in an Ovarian mature cystic teratoma; A Case report. *Arch Iranian Med* 2009; 12(2): 186-89.
12. Kikkawa F, Nawa A, Tamakoshi K, *et al.* Diagnosis of Squamous Cell Carcinoma arising from mature cystic teratoma of the ovary. *Cancer* 1998; 82:2249 - 2255.
13. Gupta V, Sood N. Squamous cell carcinoma arising in mature cystic teratoma. *Indian J Pathol Microbiol* 2009; 52: 271- 73.
14. Lai PF, Hsieh SC, Chien JC, *et al.* Malignant transformation of ovarian mature cystic teratoma: Computerized tomography findings. *Arch Gynecol Obstet* 2005; 271(4):355-57.
15. Acien P, Abad M, Mayol, M-J, *et al.* Primary squamous cell carcinoma of the ovary associated with endometriosis. *Int J Gyn Obst* 2010; 108: 16-20.
16. Hackethal A, Brueggemann D, Bohlmann MK, *et al.* Squamous-cell carcinoma in mature cystic teratoma of the ovary: systematic review and analysis of published data. *Lancet Oncology* 2008;9(12): 1173-1180
17. Park SB, Kim JK, Kim KR, Cho KS. Preoperative diagnosis of mature cystic teratoma with malignant transformation: analysis of imaging findings and clinical and laboratory data," *Archives Gynecol Obstet* 2007;275(1):25-31